DOI: 10.7860/NJLM/2026/89516.3016

Original Article

Pathology Section

Diagnostic Concordance between Bronchoalveolar Lavage Fluid Cytology and Histopathological Diagnosis of Lung Cancer: A Cross-sectional Study

RUTU RAJESWARI DALEI[1], MEENAKSHI MOHAPATRO[2], FAKIR CHARAN MUNDA[3], SADASIBA PADHY[4], PRASANNAJIT BHOI[5], ASARANTI KAR[6]

BY-NC-ND

ABSTRACT

Introduction: Bronchoalveolar Lavage (BAL) is a minimally invasive procedure that enables the collection of distal airways and the alveolar environment to make diagnoses of infectious as well as non-infectious respiratory tract diseases. It is a safe and reliable method considered for diagnosis.

Aim: To evaluate the concordance between bronchoalveolar lavage (BAL) cytology and histopathological findings in biopsied lung lesions for the diagnosis of malignancy.

Materials and Methods: It was a cross sectional study carried out in the Department of Pathology, Srirama Chandra Bhanja Medical College, Cuttack, Odisha. Patients clinically suspected of lung malignancy or other respiratory lesions undergoing BAL between March 2022 and August 2025 were included. BAL cytology data were obtained from records, and wherever available, consecutive histopathology was performed for cytohistopathological concordance.

The parameters studied included BAL sample adequacy, cytological diagnosis (positive, suspicious, negative, or inadequate), and histopathological diagnosis (epithelial malignancy, suspicious, negative, nonepithelial malignancy, or inconclusive). Diagnostic performance was assessed using sensitivity, specificity, Positive Predictive Value (PPV), and Negative Predictive Value (NPV), with 95% confidence intervals. Agreement was assessed using Cohen's kappa coefficient and discordant proportions by the McNemar test. Histopathology was considered the gold standard. For diagnostic accuracy calculations, suspicious BAL cytology cases were treated as negative and suspicious histology cases were excluded from malignant counts. Inadequate BAL samples and inconclusive histology were also excluded. Statistical analysis was performed using Microsoft Excel 2019 and International Business Machines (IBM) Statistical Package for the Social Sciences (SPSS) Statistics version 24.0.

Results: In this crosssectional study, 340 patients underwent BAL, with a mean age of 53.28±12.46 years and a Male-to-female ratio (M:F) of 1.24:1.The age range was 7 to 85 years, which is clinically notable and includes rare paediatric cases. Adequate cytological material was obtained in 306 cases (90.0%), while 34 (10.0%) were inadequate for evaluation. Of the total BAL samples, six cases (1.8%) were reported positive for epithelial malignancy, 14 (4.1%) were suspicious, and 286 (84.1%) showed no malignant cells. Histopathological biopsy was available in 62 patients (18.2%). Among these, 34 cases (54.8%) were confirmed as epithelial malignancy, 15 (24.2%) were negative, 4 (6.5%) were suspicious, and 3 (4.8%) were diagnosed as nonepithelial malignancies. For diagnostic accuracy analysis, only these 62 biopsied cases were considered, with suspicious BAL cytology cases treated as negative. After excluding inadequate Bronchoalveolar Lavage Fluid (BALF) samples and inconclusive/suspicious histology (n=12), diagnostic performance was re-calculated. When BAL cytology was compared with histopathology, specificity and PPV were both 100.0% (95% CI: 78.1-100.0), while sensitivity was 15.8% (95% CI: 6.0-31.3) and NPV was 28.9% (95% CI: 17.1-43.6). Cohen's kappa coefficient was 0.18 (95% CI: 0.05-0.31), indicating poor agreement beyond chance.

Conclusion: The findings of the present study indicate that bronchoalveolar lavage (BAL) cytology is a highly specific diagnostic tool for detecting malignancy in lung lesions. However, its relatively low sensitivity limits its utility as a standalone screening method. Since BAL fluid primarily samples the lower respiratory tract, malignant lesions may not always be adequately represented in the specimen. The limited sensitivity may also be attributed to procedural factors and challenges in cytological interpretation. Therefore, BAL cytology should be considered a complementary diagnostic modality, used in conjunction with bronchial brushings and histopathological examination, for the accurate diagnosis of lung malignancies.

Keywords: Sensitivity and specificity, Predictive value of tests, Early detection of cancer, False negative reactions, Respiratory tract diseases

INTRODUCTION

The BAL was initially proposed as a therapeutic approach to remove secretions in alveolar proteinosis and bronchial asthma. It was later popularised as a diagnostic procedure by Reynolds HY [1]. The technique involves introducing a bronchoscope into the tracheobronchial tree, instilling 100-200 mL of normal saline, and retrieving the fluid in successive aliquots. A return of ≥30% is considered adequate. The lavage fluid contains cellular and non-cellular material, which on microscopic examination can reveal inflammatory cells, malignant cells, microbes, and fungi. The specimen should be processed within one hour for differential cell count, chemical analysis, and microbiological study.

Lung cancer remains a major cause of morbidity and mortality, necessitating minimally invasive diagnostic procedures with high accuracy. Cytology techniques such as sputum cytology, bronchial brushing, Endobronchial Ultrasound-Guided Fine Needle Aspiration

(EBUS-FNA), and Transbronchial FNA (TBNA) have been widely used. BALF cytology is a safe and reliable method for sampling distal airways and alveolar spaces in both infectious and non-infectious respiratory disorders. Recent studies have highlighted its diagnostic utility and limitations in lung cancer [2,3].

This study was designed as an observational cyto-histopathological analysis to determine the diagnostic accuracy of BALF cytology in lung cancer. The objectives were to compare BALF cytology findings with histopathological examination, determine sensitivity, specificity, PPV and NPV, and identify reasons for discrepancies. The novelty of this work lies in its real-world evaluation of BALF cytology against biopsy-proven cases in a tertiary care setting, highlighting both strengths and limitations. The need for this study arises from the continued reliance on BAL as a minimally invasive diagnostic tool, where clarifying its accuracy can guide clinicians in cautious interpretation and reinforce the importance of biopsy confirmation in suspected lung cancer.

MATERIALS AND METHODS

This cross-sectional study was performed in the Department of Pathology, SCB Medical College & Hospital, Cuttack, Odisha, India, between March 2022 and August 2025.The study was approved by the Institutional Ethics Committee of SCB Medical College, Cuttack, Odisha (IEC Appln. No-2225 dated November 2025). BAL procedures were performed earlier as part of routine clinical care (March 2022-August 2025), and the retrospective analysis of anonymised records was undertaken only after ethics approval was obtained.

Inclusion criteria: Patients who underwent BAL for suspected lung malignancy and had corresponding histopathological biopsy reports available.

Exclusion criteria: Cases with inadequate BALF samples, poor-quality smears, or absence of histopathological correlation.

A total of 340 BAL procedures were included in the study, of which 62 cases had corresponding histopathological biopsy findings and were included in the diagnostic accuracy analysis.

Study Procedure

Histological and cytological diagnoses were retrieved from the records. The entire dataset was anonymised and no patient-related information was recorded. However, the number of slides prepared, adequacy of BALF cytology and the morphological diagnosis provided were recorded. All slides were reviewed. The standard approach for BALF in the laboratory was followed: BALF was processed before qualitative and quantitative examination. BALF was analysed by a second-year postgraduate student in pathology. The fluid was centrifuged for 10 minutes at 250 g and the supernatant was discarded prior to smearing the sediment over the slides. Smears were made of alcohol-fixed and air-dried fluid. Alcohol-fixed smears were stained with Haematoxylin and Eosin (H & E) and air-dried smears with Diff-Quik as part of microscopy. If an additional cell block was required, the sediment was kept at four degrees Celsius. According to Chamberlain's criteria [4], the BALF sample should contain more than 10 alveolar macrophages per 10 high-power fields and was considered adequate.

Histopathology details: Bronchial biopsy specimens were processed routinely, stained with H & E, and reviewed by senior pathologists. Where indicated, Immunohistochemistry (IHC) was performed to confirm epithelial malignancy and to differentiate non-epithelial lesions.

The study assessed adequacy of BALF samples, morphological cytological diagnosis, concordance with histopathology, and diagnostic accuracy measures including sensitivity, specificity, PPV, and NPV.

STATISTICAL ANALYSIS

Data were recorded in Microsoft Excel. Sensitivity, specificity, PPV, and NPV for BALF diagnosis were calculated, taking histological diagnosis as the gold standard. Sensitivity was calculated as true positive/(true positive + false negative); specificity as true negative/(true negative + false positive); PPV as true positive/total positive; and NPV as true negative/total negative. Cohen's kappa coefficient was applied to measure agreement between BALF cytology and histopathology. The McNemar test was used to assess statistical significance of discordant results and to derive p-values using SPSS 24. Causes of discordant findings were also explored.

Definitions:

- TP (True Positive): BALF cytology positive, histopathology malignant
- FP (False Positive): BALF cytology positive, histopathology non-malignant
- FN (False Negative): BALF cytology negative, histopathology malignant
- TN (True Negative): BALF cytology negative, histopathology non-malignant
- Sensitivity= TP ÷ (TP + FN)
- Specificity= TN ÷ (TN + FP)
- PPV = TP ÷ (TP + FP)
- NPV = TN ÷ (TN + FN)

RESULTS

The BALF sampling was performed in 340 cases during March 2022-August 2025. The mean patient age was 53.28 ± 12.46 years, with a male to female ratio of 1.24:1. The age range was 7 to 85 years, which is clinically notable and includes rare paediatric cases. BAL cytology adequacy was achieved in 306/340 cases (90.0%). Among evaluable samples, 6 cases (1.8%) were positive for epithelial malignancy [Table/Fig-1-3], 14 cases (4.1%) were reported as suspicious for malignancy, and 286 cases (84.1%) were negative. Thirty-four cases (10.0%) were inadequate [Table/Fig-4] summarises the BALF cytology findings.

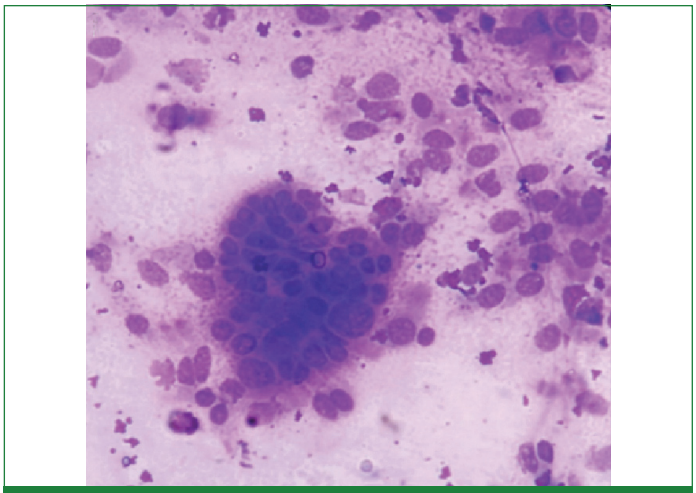

[Table/Fig-1]: BALF cytology showing atypical cells having high nucleocytoplasmic ratio with hyperchromatic nuclei (H&E, x200).

Histopathology was available in 62/340 cases (18.2%). Of these, 34 cases (54.8%) were confirmed epithelial malignancies [Table/Fig-5-7]. Four cases (6.5%) were reported as suspicious, six cases (9.7%) were inconclusive, 15 cases (24.2%) were negative for malignancy (benign inflammatory lesions, infectious conditions, and reactive changes), and two cases (3.2%) were inadequate. Three non-epithelial malignancies (4.8%) were identified on histopathological examination, comprising two mesenchymal neoplasms and one germ cell tumour. All three cases yielded inadequate BAL fluid cytology. The cytohistological concordance is summarised in [Table/Fig-8].

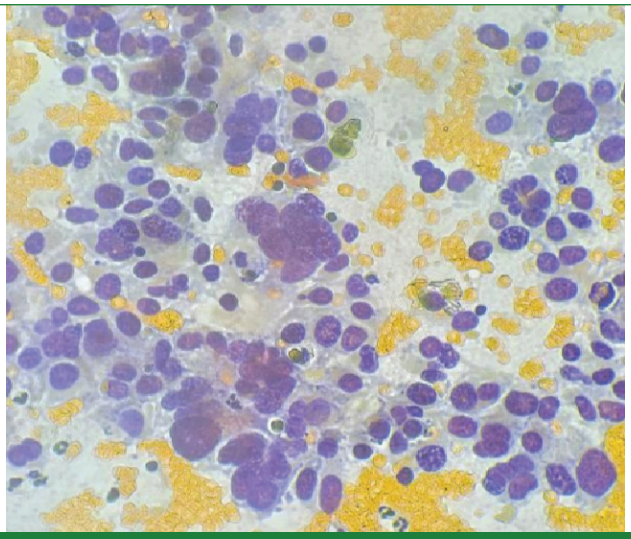

[Table/Fig-2]: BALF cytology smears: Groups of atypical cells with acinar formation (H&E, x400).

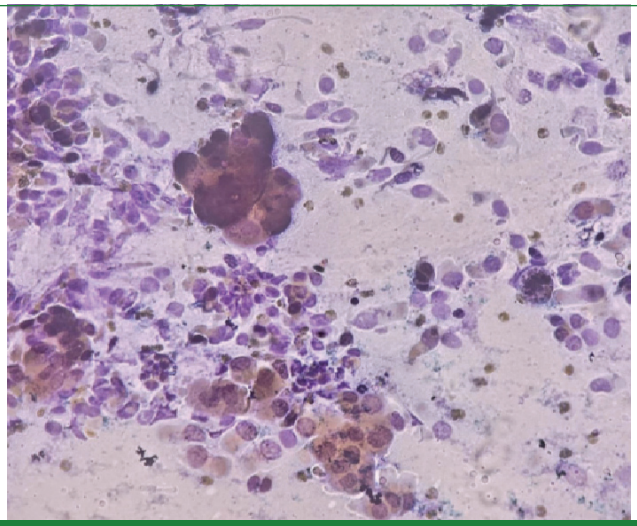

[Table/Fig-3]: BALF cytology smears showing malignant epithelial cells with hyperchromatic nuclei and dense eosinophilic cytoplasm consistent with squamous morphology (PAP, x400).

Diagnosis	Diagnosis	Percentage
Inadequate	34	10%
Negative for malignancy	286	84.10%
Suspicious	14	4.11%
Positive for malignancy	6	1.76%
Total	340	100%

[Table/Fig-4]: Cases reported on BAL.

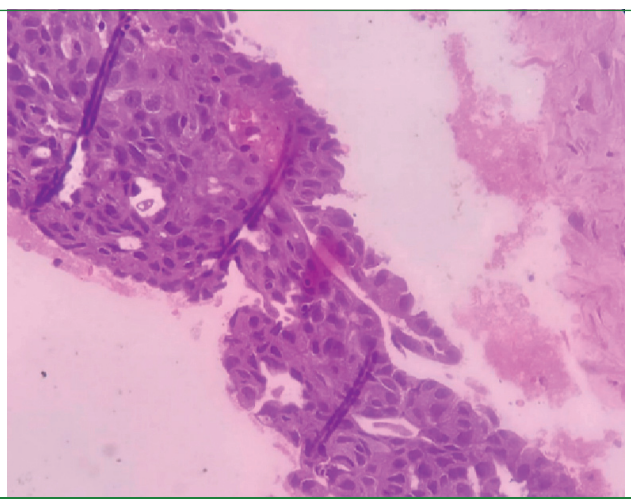

[Table/Fig-5]: Histopathological examination showing tumour cells arranged in a vague acinar pattern, suggestive of adenocarcinoma (H&E, ×100).

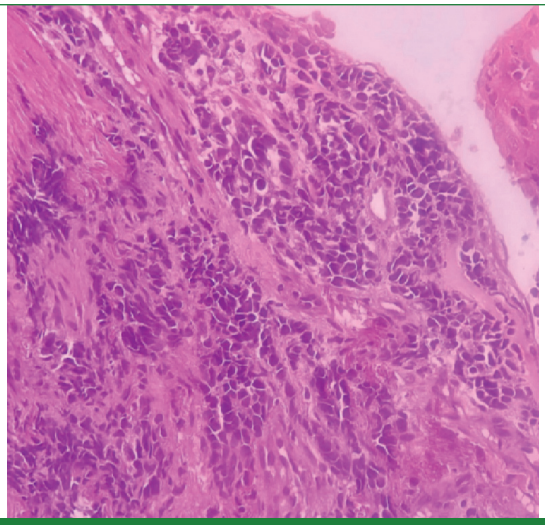

[Table/Fig-6]: Histopathological examination showing small round tumour cells with hyperchromatic nuclei arranged in a nested pattern, suggestive of small cell carcinoma (H&E, ×200).

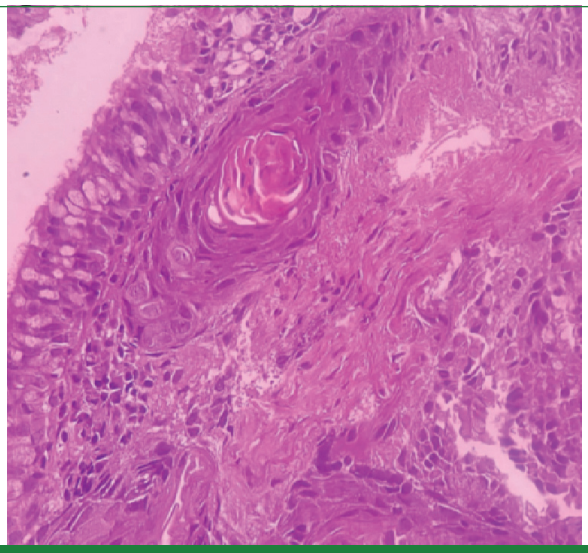

[Table/Fig-7]: Histopathological features of squamous cell carcinoma showing tumour cells arranged in nests with parakeratotic keratin pearl formation (H&E, ×200).

Tumour type	No of cases	Percentage (%)	BALF diagnosis
Inconclusive	6	9.67%	All 6 negative
Negative for malignancy	15	24.19%	2 inadequate 13 negative
Suspicious	4	6.45%	4 suspicious
Epithelial malignancy: Adenocarcinoma Squamous Cell Carcinoma (SCC) Not defined	(34) 18 9 7	(54.83%) 29.03% 14.51% 11.29%	2 positive 32 negative
Non epithelial malignancy	3	4.83%	3 inadequate
Total	62		62

[Table/Fig-8]: Concordance between histopathological diagnosis and corresponding group-wise BALF cytological diagnosis.

For diagnostic accuracy analysis, suspicious cytology cases were treated as negative, and suspicious histology cases were excluded from malignant counts to avoid inflation of prevalence. After excluding inadequate BALF samples and inconclusive/suspicious histology (n=12), diagnostic performance was recalculated. The specificity of BALF cytology compared with histopathology was 100.0% (95% CI: 78.1-100.0), with a PPV of 100.0% (95% CI: 63.1-100.0). The sensitivity was 15.8% (95% CI: 6.0-31.3), and the NPV was 28.9% (95% CI: 17.1-43.6) [Table/Fig-9]. Cohen's kappa coefficient was 0.18 (95% CI: 0.05-0.31), indicating poor agreement beyond chance. The McNemar test confirmed significant discordance between BALF cytology and histopathology (p<0.001).

The discordant pair counts used for McNemar testing are now itemised in [Table/Fig-3].

	Histopathology Malignant/ Suspicious	Histopathology Non-malignant	Total
BALF positive	TP=6	FP=0	6
BALF negative	FN=28	TN=13	41
Total	34	13	47

[Table/Fig-9]: Diagnostic concordance of BALF cytology with histopathology. (Suspicious cytology cases were treated as negative; suspicious histology cases were excluded from malignant counts.)

Further analysis of discordant cases revealed 32 mismatches (epithelial cancers only). Non-epithelial malignancies were excluded from accuracy analysis and therefore not counted among discordant cases. Among epithelial tumours undiagnosed cytologically, 17 (53.1%) were peripheral lesions beyond sampling reach, 7 (21.9%) had dense inflammatory backgrounds obscuring tumour cells, and 8 (25.0%) were adequate but negative even on reassessment, suggesting procedural limitations.

Inconclusive histopathology referred to biopsy specimens where tissue was either insufficient or showed nonspecific changes, preventing a definitive diagnosis. These cases were excluded from accuracy calculations. IHC was performed wherever adequate tissue was available and morphology was equivocal. However, in inconclusive cases, the biopsy material was too scant or exhausted, and therefore IHC could not be applied.

Histopathological diagnosis was available in 62 cases out of the 340 BAL procedures (18.23%). These biopsy-proven cases formed the basis for concordance analysis between BALF cytology and histopathology.

Diagnostic Accuracy Measures:

Sensitivity= 6 ÷ (6 + 28) = 15.8%

Specificity= 13 ÷ (13 + 0) = 100.0%

Positive Predictive Value (PPV)= 6 ÷ (6 + 0) = 100.0%

Negative Predictive Value (NPV)= 13 ÷ (13 + 28) = 28.9%

DISCUSSION

Lung carcinoma is the leading cause of mortality worldwide and the second most common cancer in both men and women [4]. The increasing incidence of lung cancers has mandated the need for quick and safe investigations to diagnose it as early as possible. Initial screening can be done through bronchial cytology or BAL analysis. Cytological diagnosis requires collaboration between cytopathologists and clinicians for accurate patient management. However, the correlation of cytology with histopathology is of great diagnostic relevance. According to Chamberlain's criteria [5], an adequate BALF sample contains more than 10 alveolar macrophages per 10 high-power fields. However, adequacy can be hampered by cellularity, poor cellular preservation, or haemorrhagic smears. In the present study, the age of the patients ranged from 7 to 85 years (clinically notable, including rare paediatric cases)with a mean age of 53.28 years. The male-to-female ratio was 1.24:1. Choudhury M et al., also reported a similar age distribution among patients undergoing bronchoalveolar lavage (BAL) sampling [6]. Adenocarcinoma, which represents 29.03%, was the most commonly diagnosed lung cancer on biopsy, followed by squamous cell carcinoma (14.51%). This is in line with data from India's national cancer registry for 2022 [7]. In this study, six BAL cases were diagnosed, two malignant and four suspicious. In the current study, sensitivity was low (15.78%) due to the few true positive cases represented. In contrast, the specificity was 100%, which was higher than the 88.8% reported by Kedige AR and Dinesh US. The diagnostic accuracy in the present study was 91.6% [8]. Gaur DS et al., reported a sensitivity of 39.4% and a specificity of 89.6% for BAL fluid cytology in the diagnosis of lung cancer [9]. In the study by Radha S et al., 14.28% (13/91) of cases were diagnosed as malignant, which is similar to our data [10]. In the present case the PPV is 100%, significantly higher than that reported by Tayal S and Bhale CP [11]. The high false negative rate of the current study was either accounted for by presence of peripherally located tumours (n=17) or due to proliferation of inflammatory population that hid the tumour cells (n=7), which the authors determined to be the cause for the high false negative rate (32 cases) or discordant result in current study. In addition, multiple false negative cases were reported (Wongsurakiat P et al., and Gaur DS et al., (13/120 or 6.63%) [9,12]. Technical proficiency, volume of lavage drained or number of exfoliated tumour cells also are contributing factors. The present data are in contrast with Bhat N et al., with 31 false positive cases (3.43%) [13]. BAL is valuable in diagnosing bacterial pneumonias, tuberculous lesions, fungal infections, and malignancies, but its use in the diagnosis of cancers is limited [13]. Bronchial brushings compared with BALF cytology have been previously shown to be superior for cancer detection in lung lesions [9,14]. Despite histology as a gold standard of diagnosis, trials of Cytologic-Histologic Correlation (CHC) differences are now-a-days encouraged at a global scale. These are not only to enhance pathological practice and patient-based result but also to monitor performance and to determine which sample types are prone to error. Cytospin preparation with filter application provided significant benefits in terms of smear quality, consistent with the findings reported by Kedige AR and Dinesh US and Das G et al., [8,9]. But this method was not available in the present configuration nor in the studies by Radha S et al., as well as Tayal S and Bhale CP [10,11]. Centrifugation at 250 g for 10 minutes is employed for smear preparation at centres with limited equipment. As these smears are prepared carefully, the results are interpretable and sufficient in cytology. Additionally, liquid-based preparation has been explored, which preserves morphology and transfers over 99% cellular yield of EBUS and TBNA [15,16].

To summarise, this study highlights the high specificity and PPV of BALF cytology, confirming its reliability when malignant cells are detected. However, the low sensitivity and NPV underscore its limitations, particularly in peripheral and non-epithelial tumours where sampling challenges and inflammatory backgrounds reduce diagnostic yield. These findings align with global reports of variable concordance between cytology and histopathology, reinforcing the need for biopsy confirmation in suspected lung cancer. While BALF remains a safe, minimally invasive adjunct for evaluating distal airways, its role should be viewed as complementary rather than definitive. By contextualising our results with published data, this study adds real-world evidence from a tertiary care center in Odisha, emphasising the importance of cytology-histology correlation to improve diagnostic accuracy and patient care.

Limitation(s)

A major limitation of the present study was the lack of histological correlation in 81.76% (278/340) of the cases. In addition, conventional slide preparation techniques were used. Compared with cytospin or liquid-based cytology, conventional preparation may result in lower cellular yield and variable smear quality, potentially limiting the assessment of cellular morphology and diagnostic accuracy. Additionally, the BALF examination has some limitations because it depends on the number of cells exfoliated from the malignant part and a few lung cancers may not exfoliate an adequate number of cells.

CONCLUSION(S)

The current data show that although BALF cytology has low sensitivity, it has excellent specificity for lung cancer diagnosis. It cannot be considered an effective screening modality. Diagnostic accuracy may vary depending on the size and site of the tumour.

The cytology of BAL fluid mostly identifies the lower respiratory tract, which may not be responsible for malignancy, as was observed in several false-negative patients. The low sensitivity may also relate to procedural and interpretative limitations. BALF cytology should be regarded as a complementary tool to bronchial brushings and histology in the diagnosis of lung cancers.

REFERENCES

[1] Reynolds HY. Bronchoalveolar lavage. Am Rev Respir Dis. 1987;135(1):250-63.
[2] Nguyen-Dang K, Bui-Thi HD, Duong-Minh N, Pham-Quang T, Nguyen-Ho L, Lam-Quoc D, et al. The role and associated factors of liquid-based cytology of bronchoalveolar lavage fluid in lung cancer diagnosis: A prospective study. Cureus. 2023;15(11):e48483. Doi: 10.7759/cureus.48483. PMID: 38073957; PMCID: PMC10704058.
[3] Sareen R, Pandey CL. Lung malignancy: Diagnostic accuracies of bronchoalveolar lavage, bronchial brushing, and fine needle aspiration cytology. Lung India. 2016;33(6):635-41. Doi: 10.4103/0970-2113.192882. PMID: 27890992; PMCID: PMC5112820.
[4] Chhikara BS, Parang K. Global Cancer Statistics 2022: The trends projection analysis. Chem Biol Lett. 2023;10(1):451.
[5] Chamberlain DW, Braude AC, Rebuck AS. A critical evaluation of bronchoalveolar lavage: Criteria for identifying unsatisfactory specimens. Acta Cytol. 1987;31(5):599-605.
[6] Choudhury M, Singh S, Agarwal S. Efficacy of bronchial brush cytology and bronchial washings in diagnosis of non-neoplastic and neoplastic bronchopulmonary lesions. Turk Patoloji Derg. 2012;28(2):142-46. Doi: 10.5146/tjpath.2012.01113.
[7] Nath A, Sathishkumar K, Das P, Sudarshan KL, Mathur P. A clinico-epidemiological profile of lung cancers in India: Results from the National Cancer Registry Programme. Indian J Med Res. 2022;155(2):264-72. Doi: 10.4103/ijmr.ijmr_1364_21.
[8] Kedige AR, Dinesh US. Role of bronchoscopic cytology in diagnosis of pulmonary lesions. J Cytol. 2023;40(1):35-41. Doi: 10.4103/joc.joc_138_22.
[9] Gaur DS, Thapliyal NC, Kishore S, Pathak VP. Efficacy of bronchoalveolar lavage and bronchial brush cytology in diagnosing lung cancers. J Cytol. 2007;24(2):73-77.
[10] Radha S, Afroz T, Prasad S, Ravindra N. Diagnostic utility of bronchoalveolar lavage. J Cytol. 2014;31(3):136-38. Doi: 10.4103/0970-9371.145636.
[11] Tayal S, Bhale CP. Diagnostic efficacy of bronchoalveolar lavage in lung malignancies. Int J Res Med Sci. 2018;6(9):2983-89. Doi: 10.18203/2320-6012.ijrms20183630.
[12] Wongsurakiat P, Wongbunnate S, Dejsomritrutai W, Charoenratanakul S, Tscheikuna J, Youngchaiyud P, et al. Diagnostic value of bronchoalveolar lavage and post-bronchoscopic sputum cytology in peripheral lung cancer. Respirology. 1998;3(2):131-37. Doi: 10.1111/j.1440-1843.1998.tb00111.x.
[13] Bhat N, Nazeir MJ, Bashir H, Bashir N, Farooq S, Fatima K, et al. Correlation of bronchial biopsy with bronchoalveolar lavage in lung malignancies. Int J Res Med Sci. 2016;4(2):428-35. Doi: 10.18203/2320-6012.ijrms20160290.
[14] Goel S, Yeshvanth SK, Asnani R, Joshi D. Accuracy of Bronchial Cytological Diagnosis in Lung Lesions in Comparison with Histopathology. J Cytol. 2022;39(4):163-168.
[15] Singh G, Agarwal P, Goel MM, Kumar M, Singh DP. Conventional vs liquid-based cytology in fine needle aspirates of lung and mediastinal masses. J Pulm Respir Med. 2017;7(2):01-05. Doi: 10.4172/2161-105X.1000400.
[16] Wang H, Wang J, Liu Y, Wang Y, Zhou Y, Yu D. Clinical values of different specimen preparation methods for the diagnosis of lung cancer by EBUS-TBNA. Diagn Pathol. 2024;19(1):61. Doi: 10.1186/s13000-024-01486-1.

PARTICULARS OF CONTRIBUTORS:
1. Senior Resident, Department of Pathology, Srirama Chandra Bhanja Medical College and Hospital, Cuttack, Odisha, India.
2. Assistant Professor, Department of Pathology, Srirama Chandra Bhanja Medical College and Hospital, Cuttack, Odisha, India.
3. Associate Professor, Department of Pathology, Srirama Chandra Bhanja Medical College and Hospital, Cuttack, Odisha, India.
4. Senior Consultant, Department of Paediatrics, Utkal Hopsital, Bhubaneswar, Odisha, India.
5. Junior Resident, Department of Pathology, Srirama Chandra Bhanja Medical College and Hospital, Cuttack, Odisha, India.
6. Professor, Department of Pathology, Srirama Chandra Bhanja Medical College and Hospital, Cuttack, Odisha, India.

NAME, ADDRESS, E-MAIL ID OF THE CORRESPONDING AUTHOR:
Dr. Meenakshi Mohapatro,
Trident Galaxy Apartments, M-202, Kalinga Nagar, Bhubaneswar-751003, Odisha, India.
E-mail: drmeenakshi1988@gmail.com

PLAGIARISM CHECKING METHODS: [Jain H et al.]
- Plagiarism X-checker: May 01, 2026
- Manual Googling: Jun 05, 2026
- iThenticate Software: Jun 11, 2026 (2%)

ETYMOLOGY: Author Origin

EMENDATIONS: 9

AUTHOR DECLARATION:
- Financial or Other Competing Interests: None
- Was Ethics Committee Approval obtained for this study? Yes
- Was informed consent obtained from the subjects involved in the study? Yes
- For any images presented appropriate consent has been obtained from the subjects. NA

Date of Submission: **Apr 03, 2026**
Date of Peer Review: **May 11, 2026**
Date of Acceptance: **Jun 12, 2026**
Date of Publishing: **Oct 01, 2026**